

## Interview with David Sarver, D.M.D., M.S.



by David Sarver, D.M.D.  
Vestavia Hills, AL  
[www.sarverortho.com](http://www.sarverortho.com)

Hugh Flax, D.D.S.  
Atlanta, GA  
[www.flaxdental.com](http://www.flaxdental.com)

**HF:** David, it's exciting to have you on our program for the AACD's 2008 Annual Scientific Session. When I've heard you lecture, it's impressive how you see the big picture of creating and maintaining a beautiful smile not only at the completion of treatment, but also throughout the aging process. While viewing "the art of the smile," what must an "esthetic orthodontist" be doing?

**DS:** Thank you, Hugh. It's exciting for me also, because of the opportunity we have to contribute to the "cross-fertilization" of knowledge and technique between all aspects of dentistry. Even though I'm an orthodontist, I have really focused in the past several years on the remarkable progress made recently in cosmetic dentistry and how we can not only collaborate in interdisciplinary care, but how the very same principles of esthetic dentistry are applied to my orthodontic cases to further enhance my outcomes.

I have long had an interest in the aging process on the face and how important it is for us to understand how this has an impact on our orthodontic decisions. As orthodontists, we often are the first in line in to make decisions that can affect a child's facial appearance for his or her lifetime. This can be positive... or it can be negative. The reduction in extraction rates in orthodontic cases can, in large part, be attributed to the recognition that loss of lip and facial soft tissue support is a normal aging process. The transition to orthodontic thinking is pretty simple: Reduction in dental volume in some facial types results in less lip and soft tissue support, thus accelerating the aging characteristics of the face and perioral apparatus. However, a word of caution—anything can be overdone and overexpansion is not recommended.

As far as the smile is concerned, substantial data indicate that incisor display diminishes with age. For the orthodontist, that means that smile evaluation must include the measurement of both maxillary incisors is displayed at rest and how much on smile. This gives us at least a start



**Figure 1:** This young patient was first seen for treatment of the maxillary midline diastema. Her clinical exam demonstrated a flat smile arc with inadequate incisor display on smile.

in gauging where our patient's smile is on the age scale. Think about this: When we look at texts in plastic surgery, orthodontic, and cosmetic dentistry, the facial and "ideal smile" illustration is usually a 25-year-old female. In reality, most of our orthodontic patients are 10 to 14 years old. Simply put, when I finish treatment on a 14-year-old, I want the child to look like a 14-year-old, not like a 25-year-old. If they look 25 when I finish their orthodontic treatment at age 14, then when they are 25 their smile will look 35! In other words, what the appliance "should be doing" is to be cognizant of how the smile ages and to place the teeth in the smile framework to account for this characteristic.

Let's use an actual patient as an example. The patient shown in Figure 1 was brought in by her parents for treatment of what was obvious to them—the maxillary midline diastema.



**Figure 2:** In addition to closing the diastema, the plan was directed to increase anterior tooth display. The resulting smile display was much more youthful in appearance.

These parents (and many other parents of adolescents) are aware of what their own orthodontic experiences were like, and think only about "crooked teeth." On clinical examination, we noted that the patient showed about 3 mm of upper incisor at rest (5 to 6 mm is desirable in that age group) and 8 mm of upper incisor display on smile. Crown height was 10 mm. We differentially placed her brackets and adjusted the mechanics in such a way that the upper incisors were brought down and the anterior maxilla were encouraged to develop more vertically. The resulting smile display was much more appropriately youthful in appearance (Fig 2). A photograph of the patient 10 years later (Fig 3) demonstrates how this expansion of orthodontic vision has contributed to the beauty of her facial and smile appearance into adulthood.



**Figure 3:** The smile 10 years after completion of treatment

**HF:** *Why hasn't contemporary orthodontics kept pace with this concept?*

**DS:** That is an interesting question. I have had the privilege of co-authoring with Bill Proffit his classic orthodontic text, *Contemporary Orthodontics*. This text is considered the standard in orthodontics and, in the latest edition, we have placed great emphasis on the issues we have just discussed. However, you and I both know that textbooks tend to be read by students who have to read them; and that most practicing clinicians are not likely to read any textbook from cover to cover. So, in my mind, contemporary orthodontics is certainly on pace with smile concepts, but knowledge disseminates at varying rates into our profession just as it does in all areas of dentistry.

**HF:** *Orthodontists tend to have a fairly standard set of records, which take into account many static relation-*

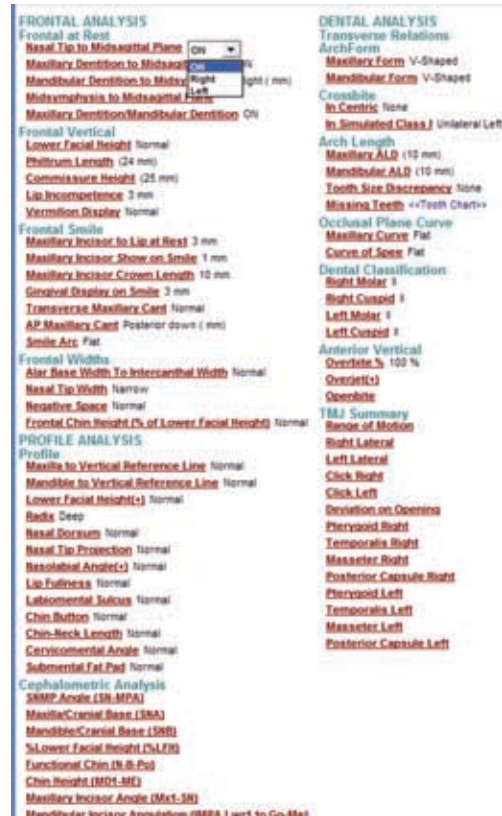

Figure 4: Computer databasing programs facilitate the clinical examination and store the information we measure in a retrievable and systematically usable format.

ships of hard tissues. Please share with us what you believe should be the new standard of documentation and treatment planning in orthodontics.

**DS:** The standard record of three facial photographs and six intraorals is still pretty much the gold standard, but we supplement those records with images of the close-up smile, oblique facial, and oblique smile. We augment intraoral pictures with what are fairly standard cosmetic dental images—the anterior teeth with a black background to highlight contacts, connectors, embrasures, halos, etc.

The major change in our orthodontic records is not only the addition of some images, but that we also teach the use

of what we term *biometric measurement* (which simply means direct measurement of the resting and dynamic relationships of hard to soft tissue). The measurement of upper incisor at rest and on smile is a perfect example. This is information not available from models, cephalometric measurements, or photographs. We have also developed computer-database programs that greatly facilitate the clinical examination and store the information we measure in a retrievable and systematically usable format (Fig 4).

**HF:** *What are the differences in “smile styles” that patients exhibit, and why it is important during treat-*

*ment to be able to view a “repeatable” smile?*

**DS:** The stages of the smile are made up of several components: (1) the smile is initiated by muscle bundles origination from the dense fascia of the nasolabial fold; (2) this upward movement is then combined with the levator muscles and; (3) when these contract, the upper lip is pulled upward and backward towards the nasolabial fold. The term *smile style* was first coined by the plastic surgeon L.R. Rubin in 1974, who defined three types of smile styles<sup>1</sup>

- *Commissure smile.* In this, the corners of the mouth turn upward due to the pull of the zygomaticus major muscles.

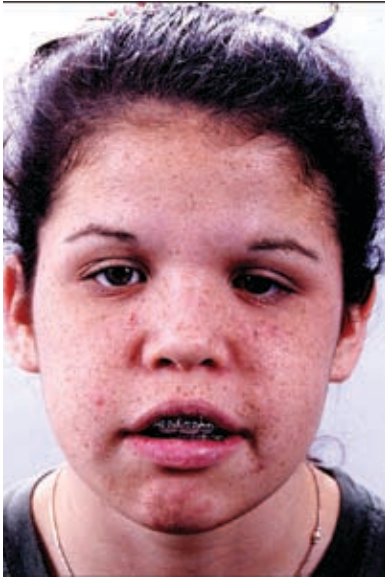

Figure 5: The short philtrum exhibited in this patient is a vexing problem in treatment planning. It represents an esthetic issue both at rest and on smile.

This is also referred to as the "Mona Lisa smile."

- *Cuspid smile.* In this smile, the upper lip is elevated uniformly so that the corners of the mouth turn upward at the same time (i.e., the entire lip rises like a window shade).
- *Complex smile.* Here, the upper lip moves superiorly as in the cuspid smile but the lower lip also moves inferiorly in similar fashion. This is termed the "starburst smile."

The smile style is important because of the difference in how much the upper and lower dentitions are demonstrated upon smiling. For example, the commissure smile may show more tooth posteriorly than anteriorly; and, in the orthodontic case, may require some incisor extrusion; and, in the restorative case, may allow some leeway as far as gingival margin placement.

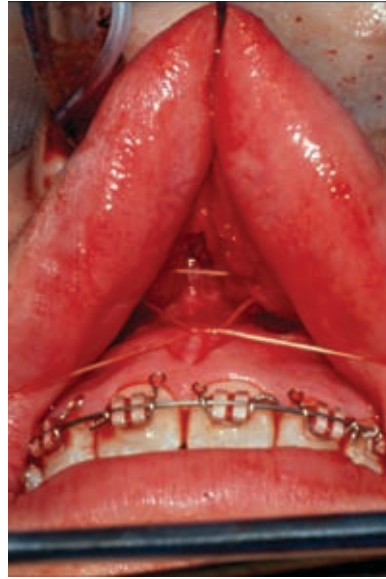

Figure 6: The V-Y cheiloplasty goes beyond the alar cinch by the use of vertical orientation of the incisions and closure, lengthening the resting length and demobilizing the upper lip.

The cuspid smile tends to be associated more with excessive gingival display, and also is associated with "hypermobile lip," which can be affected through plastic surgery techniques, specifically the V-Y cheiloplasty. We utilize the V-Y cheiloplasty to lengthen the short lip, and to demobilize the smile with a natural appearance. In V-Y cheiloplasty, an incision is made in the anterior maxilla in the vestibule, with a vertical incision behind the philtrum. Mattress sutures are then used to close these incisions, resulting in a vertical scar closure, and reorientation of the muscles to reduce the mobility of the upper lip on smile (Figs 5-7).

The complex smile means that the lower incisors are going to be on display more than in the other two smile types. For the orthodontist, this means that the lower incisors hold as

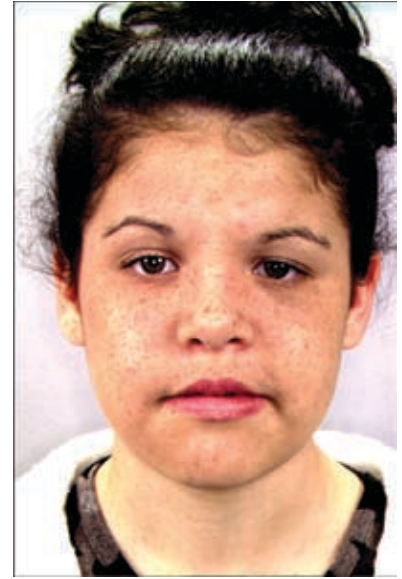

Figure 7: The final resting relationship of the upper lip demonstrates an improved Cupid's bow, lip competence, and longer philtrum

much importance as the maxillary incisors. In the veneer case, the shade differential from the maxillary teeth to the mandibular incisors may be so great that the lower incisors are also indicated for restoration.

The importance of the repeatable smile is very much like centric relation and centric occlusion. In the treatment of the smile, we recommend a consistent evaluation. There are two defined types of smiles: The *unposed* (spontaneous) smile and the posed smile. The unposed smile is involuntary and reflects emotion. Lip elevation in the unposed smile often is more animated, as seen in the laughing smile, for example. The posed smile is a learned smile, with lip animation being fairly reproducible similar to the smile that may be rehearsed for photographs or school pictures. The posed smile, because of its




Figure 8: Utilizing digital video clips with segmentation of the flow of images results in a "smile curve" that helps us determine the repeatable and most consistent smile.

repeatability, is considered the "treatment" smile.

In clinical practice, standard records include film or digital photographs, radiographs, and study models (mounted or unmounted plaster or electronic models). Universal standard facial images consist of the frontal at rest, frontal smile, and profile at rest images. Although these orientations provide an adequate amount of diagnostic information, they do not contain all the information needed for smile evaluation and quantification. To treat the smile, we need to expand our records, and we use computerized databasing of direct clinical examination.

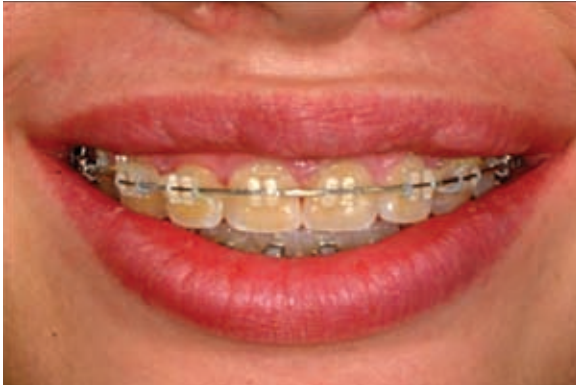Records needed for contemporary smile visualization and quantification can be divided into two groups: Static and dynamic. We recommend that in addition to the accepted three facial image orientations, pho-

tograph recordings should also include profile, oblique, and frontal close-up smiles. We have also been utilizing dynamic recordings of smiles and speech with digital videography. Digital video and computer technology enables us to record anterior tooth display during speech to smiling at the equivalent of 30 frames per second. We typically take five seconds of video for each patient, yielding 150 frames for comparison. These clips allow us to visualize the smile from beginning to end, and to produce what I term the *smile curve* (Fig 8). The smile curve allows us to visualize the greatest number of frames that appear to be the same, (i.e., the sustained smile consistent with definition of the posed smile).

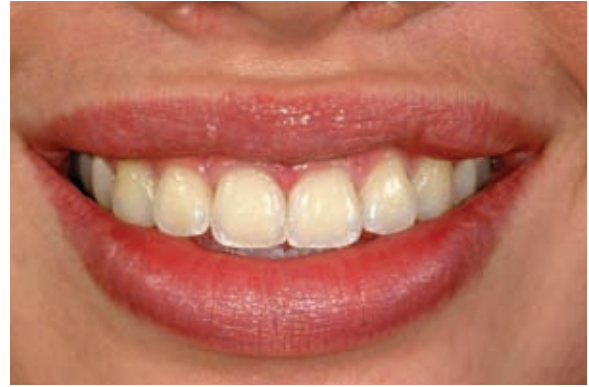**HF:** *All of our AACD members will appreciate the importance of the "smile curvature" and "buccal corridor" in creating a fully displayed smile. What are some of the impor-*

*tant dimensional considerations needed to create an ideal smile?*

**DS:** The concepts of "smile curvature" and "buccal corridor" are smile attributes that have been around for quite some time. Smile curvature (in orthodontics, we term this the *smile arc*) relates to the curvature of the maxillary occlusal plane and the curvature of the lower lip on smile. If they are parallel, they are termed *consonant*; and, if they are not, they are *flat* or *reverse*. Buccal corridor refers to the "dark spaces" in the corners of the smile and is defined as the space between the outermost dental component and the inner commissure in the smile framework. Interestingly, while these concepts are very hot topics now, they originated in the early 1950s from Frush and Fisher,<sup>2</sup> both denture prosthodontists. Their description defined inappropriate denture esthetics; in other words, a denture that does not look natural



*Figure 9: This patient was nearing the end of orthodontic treatment, and her smile arc was somewhat flattened as an unfortunate result of orthodontic treatment.*



*Figure 10: But recovery was possible, after reassessment and placement of brackets to increase incisor display and improvement of the consonance of the smile arc.*

is characterized by a flat smile arch, or obliterated buccal corridors.

In the past several years, we have seen two studies that reveal that in as many as one third of our cases, we are flattening smile arcs as part of orthodontic treatment.<sup>3,4</sup> There are many reasons for this, including skeletal pattern, regimented bracket placement, the focus on cuspid guidance (resulting in incisor intrusion when extruding cuspids) and many other factors. If your readers are interested, they may go to [www.sarverortho.com](http://www.sarverortho.com) and download (in the "Professional" section) the article on smile arc and the importance of upper incisor position in the smile. An example of an orthodontically flattened smile arc is depicted in Figure 9. In this case, we simply reset the maxillary and mandibular anterior brackets more superiorly to provide extrusion to the upper incisors and reestablish the smile arc curvature (Fig 10).

While Frush and Fisher<sup>2</sup> described very broad arch forms as being unesthetic in dentures,

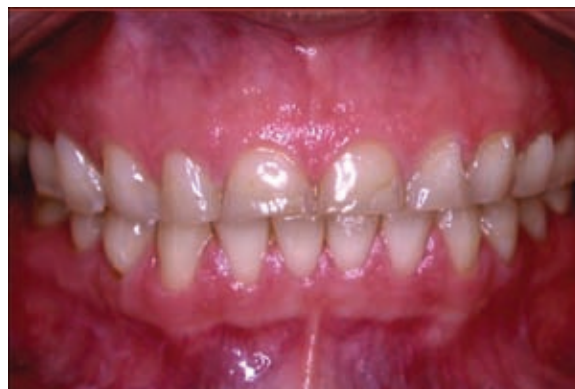it turns out that several orthodontic studies indicate that, essentially, the wider the better.<sup>5-7</sup> Now we are much more careful in bracket placement so that smile arcs are not flattened, and we are selecting arch forms that are broader. This broader arch form concept for esthetics is in conflict with some other orthodontic goals; namely, stability of result. Long-term research from the University of Washington<sup>8</sup> clearly shows that canine expansion is an unstable movement (in any event, intercanine width diminishes as we get older). Therefore, expansion of the intercanine width is discouraged. So how do we get broader smiles for esthetic purposes, but also obey the stability rules? Some limited studies<sup>9</sup> indicate that premolar expansion is indeed stable, and when we want to improve the width of the smile for esthetics, we try to expand premolar but not expand the intercanine width.

**HF:** *Perioral soft tissues have a great impact on smile esthetics. Please explain your thoughts on how aging affects the lips and subsequently the smile.*

**DS:** Well, abundant lip support is considered esthetically desirable in today's society, especially for females. You only have to pick up a couple of fashion magazines and look at the cover and advertisements to see that lip fullness is "in." Long-term studies in orthodontics<sup>10,11</sup> have documented the general principle of aging of the lips—that there is loss in lip thickness from age 14 onward—particularly more in the upper lip than the lower lip. Therefore, maintaining of or improving lip balance is part of our goal in treatment planning. While increasing lip support may seem to be only an orthodontic or surgical possibility, in reality, how veneers are designed can also improve lip support. The patient seen in Figure 11 is an example. She asked what might be done to improve her smile. I explained that her problem was not an orthodontic one, but one of dental attrition (Fig 12); and that she needed her dentist's help more than mine. Noting that she had fairly thin lips, downturned commissures, and lack of lip support,



*Figure 11: This patient presented for orthodontic smile improvement. Her smile was characterized by diminished incisor display, tooth shade issues, and loss of crown height.*



*Figure 12: The root cause of her smile problem was one of severe dental attrition.*

her dentist proceeded to minimally prepare his veneers. By adding incisor length he not only added support to the upper lip, but also some eversion to the lower lip, improving lip fullness. This patient's final smile is shown in Figure 13 and the increased lip support in Figure 14.

**HF:** *I love your idea that "rules" should not always be adhered to but, rather, be interpreted as guidelines in treatment planning. Why is it important to focus not just on the problems that our patient's present to us, but also to preserve what is right about someone's appearance?*

**DS:** The answer to this question really revolves around our teaching that dentistry is both art and science. Rigid measurements as "ideals" or "rules" simply are not applicable on the individual any more than rules exist on what makes a "good" painting.

Each individual has his or her own attractive attributes. What looks good for one person may not look good on another; and, as clinicians we must be careful not to force our own concepts and "ideal" on our patients.

In medicine and in dentistry, we have been taught the "problem-oriented" treatment-planning model. In this scenario, we identify all the problems that the patient has and then execute a treatment plan to solve as many problems as possible. Where the hazards lie is in not recognizing the positive attributes a patient has, and in adversely affecting them in the pursuit of correcting the problems. The classic orthodontic example in is the patient with a Class II malocclusion because of a deficient mandible. If Class I occlusion is the problem, then extraction of maxillary premolars and retraction of the incisors to reduce overjet and

attaining Class I cuspid relationships solves the "problem." However, if we have not recognized that the midface may be ideal and we are distorting the midface to fit the occlusal goals, we have adversely affected a positive attribute. In smile esthetics, a good example is the orthodontic patient who has a moderately "gummy" smile. In opening a deep bite in these patients, we may elect to intrude upper incisors to reduce gumminess to the smile. However, if the smile arc is consonant and we intrude maxillary incisors, we unfortunately flatten the esthetic smile arc.

**HF:** *One of the exciting things that we are doing at our Annual Scientific Session next May in New Orleans is bringing together the "Birmingham Team" of you, AACD member Dr. Paul Koch, and plastic surgeon Dr. Danny Rousso to show the dynamics of interdisciplinary*



*Figure 13: Restoration with veneers included appropriate crown thickness and length resulting in more incisor display, better tooth color, and a consonant smile arc.*



*Figure 14: The length and soft tissue support resulted in improved lip support—a youthful enhancement of resting lip posture.*

*care at its finest. What are some of the secrets to your success?*

**DS:** We believe that this is a commonsense application of planning in a multidisciplinary environment—and we agree that not one of us alone can provide the ultimate outcome for our patient. All of us should be educated in what the rest of the team (including the periodontist and the oral and maxillofacial surgeon) does, to avoid what I term *diagnosis by procedure*. This can best be illustrated by the aforementioned patient who has Class II malocclusion with a mandibular deficient skeletal relationship and profile. If the patient goes to the oral and maxillofacial surgeon first, then mandibular advancement is recommended. If the patient initiates the treatment with the orthodontist, then mandibular advancement may be recommended; or extraction of premolars and retraction of

incisors also may be treatment options. If the patient goes to a facial plastic surgeon, the solution is a new chin and nose, because that is what the plastic surgeon does. We all have to recognize what benefits each patient the most and achieves their goals, not ours.

**HF:** *Your presentations are famous for their dynamic and multimedia approach to showing how orthodontics is extremely critical to developing long-term beautiful smiles. What do you have in store for the AACD audience in New Orleans?*

**DS:** I have found that the best way to teach the concepts of how our faces change longitudinally is through multimedia superimposition of our images. I practice in Vestavia Hills, Alabama, a suburb of Birmingham (a medium-sized city), where the population tends to be fairly stable. By that, I mean that many of the children raised in

Vestavia often return to Vestavia either to visit their parents, or to settle. Having been in practice 28 years, I am, in many families, treating the children of children I treated years ago! These factors have allowed me to capture long-term (20 to 25 years) records on a number of my cases, and have allowed me to study aging characteristics firsthand (and learning that decisions I made 25 years ago may or may not have been particularly advantageous to my patient's long-term appearance). I am fortunate that most (but not all) of my decisions were good. In any event, we use multimedia technology to calibrate and overlay multiple images in a "morphing" pattern, which briefly demonstrates the principles we are trying to teach. We all have seen time-lapse photographs of a rose blooming; it is far more interesting to watch a child "bloom"

in front of your eyes, and then enter into middle age. These images track how our patients change over the years; they are truly fascinating.

## References

1. Rubin, LR. The anatomy of a smile: Its importance in the treatment of facial paralysis. *Plast Reconstr Surg* 53:384-387, 1974.
2. Frush JO, Fisher RD. The dynesthetic interpretation of the dentogenic concept. *J Prosthet Dent* 8:558-581, 1958.
3. Hulsey CM. An esthetic evaluation of tooth-lip relationships present in then smile. *Am J Orthodon* 57:132-144, 1970.
4. Ackerman J, Ackerman MB, Brensinger CM, Landis JR. A morphometric analysis of the posed smile. *Clin Orthod Res* 1:2-11, 1998.
5. Moore T, Southard KA, Casco JS, Qian F, Southard TE. Buccal corridors and smile esthetics. *Am J Orthod Dentofacial Orthop* 127(2):208-213, 2005.
6. Parekh S, Fields HW, Beck M, Rosenstiel S. Attractiveness of variations in the smile arc and buccal corridor space as judged by orthodontists and laymen. *Angle Orthod* 76(4):557-563, 2006.
7. Parekh S, Fields HW, Beck M, Rosenstiel S. The acceptability of variations in smile arc and buccal corridor space. *Orthod Craniofac Res* 10(1):15-21, 2007.
8. Little RM, Wallen TR, Riedel RA. Stability and relapse of mandibular anterior alignment-first premolar extraction cases treated by traditional edgewise orthodontics. *Am J Orthod* 80(4):349-365, 1981.
9. BeGole EA, Fox DL, Sadowsky C. Analysis of change in arch form with premolar expansion. *Am J Orthod Dentofacial Orthop* 113(3):307-315, 1998.
10. Vig RG, Brundo GC. Kinetics of anterior tooth display. *J Prosthet Dent* 39(5):502-504, 1978.
11. Dickens S, Sarver DM, Proffit WR. The dynamics of the maxillary incisor and the upper lip: A cross-sectional study of resting and smile hard tissue characteristics. *World J Orthod* 3:313-320, 2002.

*AF*

